

Imaging and arrhythmia

Reza Razavi

Division of Imaging Sciences, King's College London, Guy's Hospital, London, UK

Correspondence: Professor Reza Razavi, Division of Imaging Sciences, King's College London, 5th Floor, Thomas Guy House, Guy's Hospital, London SE1 9RT, UK.

Tel: +44 020 718 85440; fax: +44 020 718 85442; e-mail: reza.razavi@kcl.ac.uk

Abstract

Imaging is becoming increasingly important in the management of cardiac arrhythmias as treatment moves away from long-term medication to curative radiofrequency ablation (RFA). With the complexity of the arrhythmias being treated in cardiac catheterization laboratories, information from echocardiography, computed tomography, and magnetic resonance imaging (MRI) are increasingly being used in planning before the procedure, in addition to helping guide the procedures. These imaging techniques can provide information about patient-specific cardiac anatomy. In addition, MRI can provide information about myocardial motion and myocardial tissue characteristics. In the future, arrhythmia ablations may be performed entirely under MRI guidance, without the harmful effects of X-rays, and with the added benefit of real-time anatomical views.

■ *Heart Metab.* 2006;33:13–16.

Keywords: Arrhythmia, echocardiography, computed tomography, magnetic resonance imaging

Introduction

There has been a major change in the treatment of arrhythmias over the past 20 years. Most of these conditions can now be treated, and often cured, by radiofrequency ablation (RFA) [1,2]. This alleviates the need for long-term drug treatment and is often preferred by patients. There follows a brief description of the different imaging techniques used for RFA and, in particular, MRI, which is one of the newer and more promising techniques in this field.

X-ray fluoroscopy

Radiofrequency ablation procedures are traditionally carried out under X-ray fluoroscopic guidance.

Advantages:

- gives clear images of the entire length of the catheters;
- provides high temporal resolution of at least 25 frames per second;
- is an easy-to-use technology that is widely available and known by operators.

Disadvantages:

- is a projection imaging modality, and more than one view is necessary to gain an appreciation of the 3-dimensional location and path of catheters. Therefore, there is a need either to move the X-ray c-arm to obtain different projections or to use a bi-plane X-ray system;
- the anatomical context of the acquired images can be difficult to interpret, because soft tissues, such as the heart and blood vessels, are not visible during X-ray exposure;
- X-ray imaging delivers a dose of radiation to the patient and those carrying out the procedure. This can be significant for prolonged procedures and in pediatric cases [3].

Echocardiography

Echocardiography is used as an adjunct to assess cardiac anatomy and function before an RFA procedure, and to look for the presence of complications

Metabolic imaging

Reza Razavi

such as pericardial effusion after a procedure. Intra-cardiac echocardiography is becoming adopted for use during the procedure [4].

Advantages:

- intra-cardiac echocardiography allows real-time visualization of patient-specific cardiac anatomy and the ablation catheter – particularly useful for assessing contact between the two;
- the technique does not involve administration of a dose of X-ray radiation.

Disadvantages:

- cost – the probes are expensive and, in some countries, can be used only once;
- an additional large sheath is required for vascular access;
- at present this technique provides only 2-dimensional information, although 3-dimensional systems are being developed.

Electroanatomic mapping systems

The mainstay of the planning of RFA procedures is electrical mapping of the heart. However, increasingly, the anatomical shape of the vessels and chambers of the heart has become important, especially in ablation of atrial fibrillation. In the past few years, a number of electroanatomic systems have been developed, such as CARTO [5] and EnSite [6], that bring together the 3-dimensional representation of the anatomy and the electrical mapping.

Advantages:

- there is potentially little or no dose of X-ray radiation;
- a 3-dimensional representation of the surface of the heart is obtained;
- combined electrical and anatomical information are provided;
- the technique affords the ability to mark, and thus return to, the position of the ablation catheter on the surface of the heart.

Disadvantages:

- cost – particularly with the CARTO system, which requires dedicated catheters;
- additional time is needed to build an anatomical surface by contact mapping of the cardiac chamber;

- there may be errors in the anatomical surface that is depicted by this technique, which can make the heart rather spherical, although this can be improved by importing computed tomographic information;
- there is no correction for respiratory motion.

Computed tomography

Computed tomography is very helpful in the preplanning for atrial fibrillation ablation, as it provides images of the pulmonary veins and left atrium that have a high spatial resolution. It can also be combined with electroanatomic systems such as CARTO [7] or, as has been done more recently, with real-time X-ray fluoroscopic images [8].

Advantages:

- the technique gives consistent high spatial resolution images of the heart;
- it is relatively fast and the images are easy to acquire;
- it provides 3-dimensional information.

Disadvantages:

- the technique involves an additional dose of X-ray radiation that can be substantial;
- as imaging is performed hours, and even days, before the procedure, it does not take into account any changes to the shape and size of the heart that can take place before or during the procedure;
- when the technique is combined with electroanatomic systems or X-ray fluoroscopy, no correction is made for respiratory motion.

Magnetic resonance imaging

Magnetic resonance imaging can provide anatomical information similar to that obtained with computed tomography. The recent emergence of hybrid X-ray and magnetic resonance imaging systems (XMR) has opened up new interventional guidance strategies for the ablation of arrhythmias [9]. As the hybrid, these systems are also useful tools in the process of development of interventions that are fully guided by MRI.

Advantages:

- provides high-quality anatomical information;
- affords excellent 3-dimensional visualization of cardiovascular structures;
- it is possible to obtain functional information such as cardiac wall motion;

Metabolic imaging

Imaging and arrhythmia

- gadolinium late enhancement allows visualization of ablation lesions and myocardial scarring;
- there is no ionizing radiation.

Disadvantages:

- devices that are used during RFA, such as catheters, are not designed to be MRI-visible or MRI-compatible, as they often contain ferromagnetic materials or long electrical conductors. Much effort is being directed into making electrophysiology catheters that are both MRI-compatible and MRI-visible, although the routine use of such devices in patients remains to be established;
- the MRI technique can be noisy, and access to patients can be restricted;
- there is limited availability of XMR systems, and not many operators are accustomed to working in this environment.

My colleagues and I have developed an XMR guidance system for cardiovascular interventions, in particular for RFA. This system allows us to use both magnetic resonance and X-ray imaging for guidance [10]. A key step in the development of this system is to register magnetic resonance and X-ray images that are acquired during the procedure. This allows the overlay of cardiovascular anatomy recently acquired by MRI onto X-ray images, and the reconstruction of the position of catheters seen during X-ray fluoroscopy in this anatomy (Figure 1). Using this technique, we are also able to mark the position of ablation lesions on the 3-dimensional surface by automatically tracking the catheter tip. We are therefore able to delineate linear ablation lines (Figure 2).

Planned improvements to the technique include correction of the position of the MRI-derived surface to account for respiratory motion. It has been

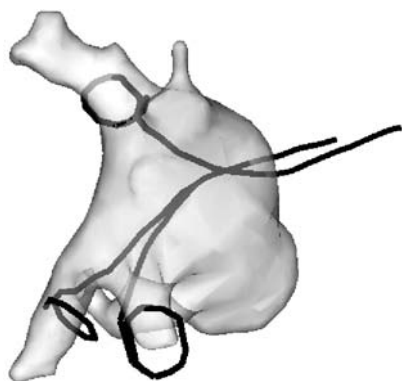


Figure 1. Magnetic resonance imaging (MRI) view of the left atrial endocardial surface showing the position of a helix ablation catheter during pulmonary vein isolation. The catheter position was derived using hybrid X-ray/MRI registration technology.

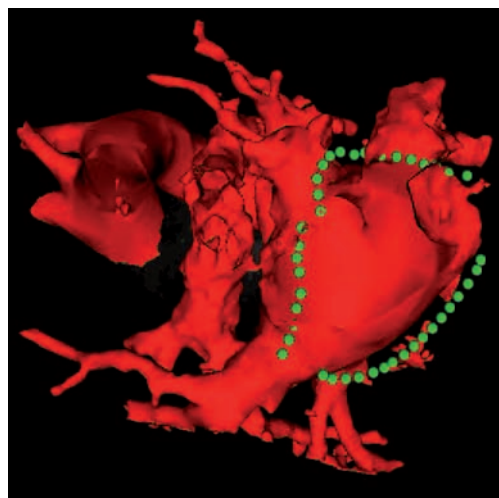


Figure 2. Magnetic resonance imaging (MRI) view of the left atrial endocardial surface (red) with the location of linear ablation points shown (green). The ablation points were marked onto the surface using hybrid X-ray/MRI registration technology during the course of the intervention.

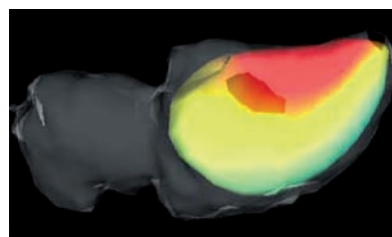


Figure 3. Magnetic resonance imaging (MRI) view of the left ventricular endocardial surface showing the mapped electrical activity during early systole. The electrical data were measured using the EnSite system and fused with the MRI data using hybrid X-ray/MRI registration technology.

possible to take electrical information from electrical mapping systems and display this on our MRI-derived surface (Figure 3). Further improvements should allow fast interpolation of sparse electrical data points so that similar electroanatomic surfaces can be built using standard electrophysiology electrodes [11]. MRI-derived myocardial wall motion information has also been combined with electrical maps derived during the same procedure [12]. This information is being used to help build computer models that, in the future, may allow us to get electrical maps from motion data (Figure 3) [13]. Finally, in common with others, we are developing the tools needed to carry out the entire ablation procedure under MRI guidance. ■

REFERENCES

1. Vatz JB, Brown EF. Diagnostic and therapeutic technology assessment. Radiofrequency catheter ablation of aberrant conducting pathways of the heart review. *JAMA*. 1992; 271:268:2091–2098. Published erratum in *JAMA*. 1993; 269:216.

Metabolic imaging

Reza Razavi

2. Saxon LA, Kalman JM, Olgin JE, Scheinman MM, Lee RJ, Lesh MD. Results of radiofrequency catheter ablation for atrial flutter. *Am J Cardiol.* 1996;77:1014–1016.
3. Kovoor P, Ricciardello M, Collins L, Uther J, Ross D. Risk to patients from radiation associated with radiofrequency ablation for supraventricular tachycardia. *Circulation.* 1998;98:1534–1540.
4. Mangrum JM, Mounsey JP, Kok LC, DiMarco JP, Haines DE. Intracardiac echocardiography-guided, anatomically based radiofrequency ablation of focal atrial fibrillation originating from pulmonary veins. *J Am Coll Cardiol.* 2002;39:1964–1972.
5. Pappone C, Oreto G, Lamberti F, et al. Catheter ablation of paroxysmal atrial fibrillation using a 3D mapping system. *Circulation.* 1999;100:1203–1208.
6. Schilling RJ, Peters NS, Davies DW. Simultaneous endocardial mapping in the human left ventricle using a noncontact catheter: comparison of contact and reconstructed electrograms during sinus rhythm. *Circulation.* 1998;98:887–898.
7. Tops LF, Bax JJ, Zeppenfeld K, et al. Fusion of multislice computed tomography imaging with three-dimensional electroanatomic mapping to guide radiofrequency catheter ablation procedures. *Heart Rhythm.* 2005;2:1076–1081.
8. De Buck S, Maes F, Ector J, et al. An augmented reality system for patient-specific guidance of cardiac catheter ablation procedures. *IEEE Trans Med Imaging.* 2005;24:1512–1524.
9. Razavi R, Hill DL, Keevil SF, et al. Cardiac catheterisation guided by MRI in children and adults with congenital heart disease. *Lancet.* 2003;362:1877–1882.
10. Rhode KS, Sermesant M, Brogan D, et al. A system for real-time XMR guided cardiovascular intervention. *IEEE Trans Med Imaging.* 2005;24:1428–1440.
11. Sermesant M, Coudiere Y, Moreau-Villegier V, et al. A fast-marching approach to cardiac electrophysiology simulation for XMR interventional imaging. *Med Image Comput Comput Assist Interv.* 2005;8:607–615.
12. Sanchez-Ortiz GI, Sermesant M, Rhode KS, et al. Localization of abnormal conduction pathways for tachyarrhythmia treatment using tagged MRI. *Med Image Comput Comput Assist Interv.* 2005;8:425–433.
13. Sermesant M, Rhode K, Sanchez-Ortiz GI, et al. Simulation of cardiac pathologies using an electromechanical biventricular model and XMR interventional imaging. *Med Image Anal.* 2005;9:467–480.